

CASE 3

42 year old bus driver is complaining of headache for last 3 months. One month ago he noticed that while he was driving he was unaware of vehicle coming from is extreme right and left side and was given ticket for his reckless driving. He has now noticed double vision since last 15 days. On examination he has dilated right pupil and his right eyeball is deviated to right and downwards. Has mild ptosis (drooping of upper lid) on right side. His visual field is as charted below.

Photo A

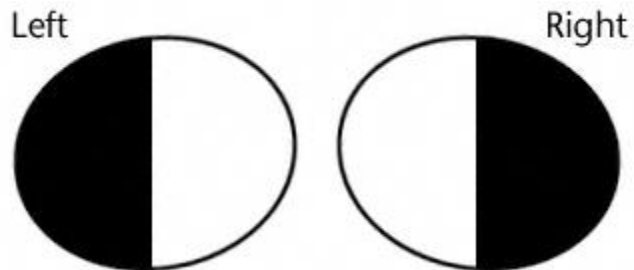


Photo B

